

PATIENT

Oliver Rossman

SPECIES

Feline

BREED

DSH

SEX

Male Neutered

AGE

11 years

WEIGHT

10lbs; 4.5kgs

INTERPRETED BY

Maggie Machen Lamy,
DVM, DACVIM
(Cardiology)

IMAGING PERFORMED BY

Loetitia St-Jacques,
LVT/RVT

HOSPITAL NAME

Mountain View

REFERRING VET

Dr. Mendoza

INVOICE

22819

DATE

2/25/22

PRESENTING CLINICAL SIGNS

History: Patient presented today for evaluation of weakness and losing balance. Patient was diagnosed with caudal pharyngeal/laryngeal irritation/swelling. CT performed showing mild splenic and hepatic enlargement. Laryngeal biopsies and C&S are pending. Possible aspiration pneumonia in left caudal lung lobe. On today physical exam P is BAR, no dyspnea noted. Equivocal 1/6 murmur and arrhythmia noted, recommended ECG evaluation to r/o cardiogenic origin of weakness

ELECTROCARDIOGRAPHIC FINDINGS

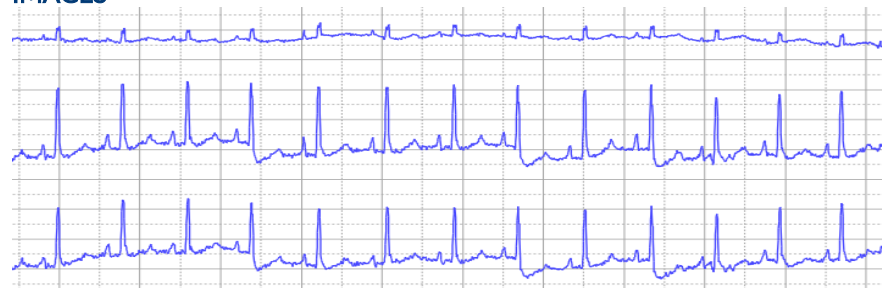
A six lead ECG is available at 25mm/s; 30mm/mV. The average heart rate is 180bpm (range 170-214bpm). The rhythm is sinus in origin, with a p for every QRS complex and vice versa. The P wave morphology is positive with a normal dimension. Normal PR. The QRS morphology is positive with normal dimension. MEA is normal. No ectopic beats, pauses or dysrhythmias observed. ECG diagnosis: Normal sinus tachycardia.

INTERPRETATION OF THE FINDINGS & FURTHER RECOMMENDATIONS

The submitted ECG is normal, with no evidence of dysrhythmias. If these findings do not reflect what was ausculted on exam (ie premature beats), a longer recording or potentially a holter monitor may be necessary.

Based upon what is seen here, no obvious arrhythmic cause for the clinical issues is suspected. While exceptions can occur, the majority of intermittent feline arrhythmias develop secondary to a primary issue (such as neoplasia or systemic disease) rather than being the cause of clinical signs. Further evaluation is advised.

IMAGES



The information and recommendations provided are based on the images presented by the referring veterinarian. No evaluation can be communicated regarding pathology that was not visible in the image/video clips provided.

Thank you for this referral. If the clinical or image interpretation does not parallel your findings or if I can be of any further assistance please contact me.

Maggie Machen Lamy, DVM
Diplomate of the American College of Veterinary Internal Medicine (Cardiology)
info@sonopath.com



Portable Animal Western Sonography, Inc.

IMAGING PERFORMED BY
pawsonography@gmail.com  530-786-8340

PATIENT

Oliver Rossman

SPECIES

Feline

BREED

DSH

SEX

Male Neutered

AGE

11 years

WEIGHT

10lbs; 4.5kgs

INTERPRETED BY

Maggie Machen Lamy,
DVM, DACVIM
(Cardiology)

IMAGING PERFORMED BY

Loetitia St-Jacques,
LVT/RVT

HOSPITAL NAME

Mountain View

REFERRING VET

Dr. Mendoza

INVOICE

22819

DATE

2/25/22